

Advanced Abdominal Pregnancy

R.K. Narone, S.S. Roy, J.N. Narone, T.K. Chatterjee
Department of Obstetrics and Gynaecology,
University Teaching Hospital,
Lusaka

SUMMARY

Two cases of advanced abdominal pregnancy have been reviewed and two live babies have been delivered. Emphasis has been given to suggestive clinical features which may help in the pre-operative diagnosis of this rare condition.

INTRODUCTION

One of the rare and unforgettable experiences in the life time of an obstetrician is diagnosing and delivering a live full term-extra-uterine abdominal pregnancy. The reported incidence of abdominal pregnancy by various authors shows it to be a rare occurrence in obstetrics. One of the earliest descriptions of advanced extra uterine pregnancy was written nearly a thousand years ago by Albucasis who flourished in Spain in the 10th Century. From that time until the beginning of the 19th century there were numerous references to isolated but interesting examples of advanced extra-uterine pregnancy. The first recorded case, in 1500, is that of the wife of Jacob Nufer where the mother and child survived.

Subsequently in the 16th, 17th and 18th centuries, cases were recorded where the foetus remained in the abdomen for 1-31 years, at times being extruded through the umbilicus in the form of bones and pus.

During the 19th century, the outstanding works of William Campbell, Johns Parrey and Lawson Tait placed conception, classification and management of advanced extra uterine pregnancy on a sound footing. The first operation in America was done by John Bard in 1759.

Material and Methods

The purpose of this paper is to present two cases of advanced abdominal pregnancy which were successfully diagnosed and delivered of live babies. Both cases were done in 1979 in the department of Obstetrics and Gynaecology in Lusaka.

A short resume is given of both the cases. Special emphasis is given to the presenting features and the clinical signs which were suggestive of abdominal pregnancy. Radiological pictures and hystero-salpingogram confirmed the diagnosis before laparotomy.

Case No. 1

F.M. was admitted on 24th October 1978 for abdominal pain, infrequent bleeding, nausea and vomiting since June. On examination, the abdomen was tender with distension all over. Cervical os was closed, fornices were tender, and there was a blood stained discharge from the vagina. A diagnosis of pelvic inflammatory disease with peritonitis was made. The most remarkable findings were severe tenderness in the left iliac fossa, guarding and rebound tenderness. On 30th October a tender mass was found arising out of the pelvis. A diagnosis was made of ovarian cyst with pregnancy or, secondary abdominal pregnancy. The gravindex test was positive.

Pieces of white necrotic tissue were passed per vaginam. A diagnosis of pelvic inflammatory disease with bleeding and continuous abdominal pain it was uncertain whether she had an extra-uterine pregnancy, or an intra uterine pregnancy associated with fibroids or an ovarian cyst.

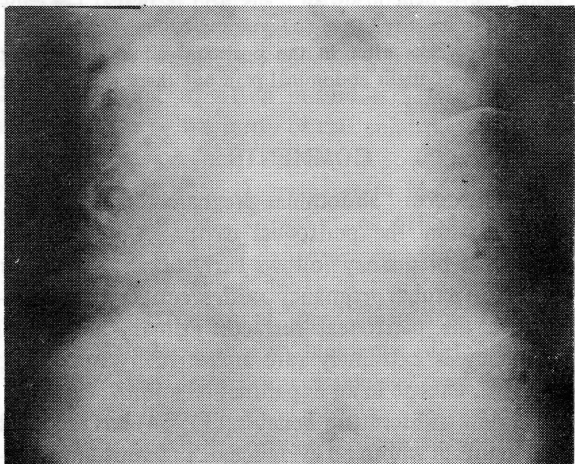
On 25th November, the patient started feeling foetal movements. The patient was discharged on 19th December 1978 although the abdominal pains continued off and on. The mass was growing in size and was 28 weeks size now and the foetal heart was heard. A presumptive diagnosis of intra uterine pregnancy was made and the patient was discharged with advice to come for follow up.

The patient was re-admitted on 17.3.79 as a case of pain in the lower abdomen and epigastric region. A foetus was palpated in the transverse lie extending from under the left hypochondrium and the epigastrium.

Anotehr 14 weeks size lump was palpated in the suprapubic region which on vaginal examination was found to be multiple fibromyoma of the uterus. A straight X-ray of the abdomen revealed a foetus in the transverse lie just under the ribs (Fig. 1).

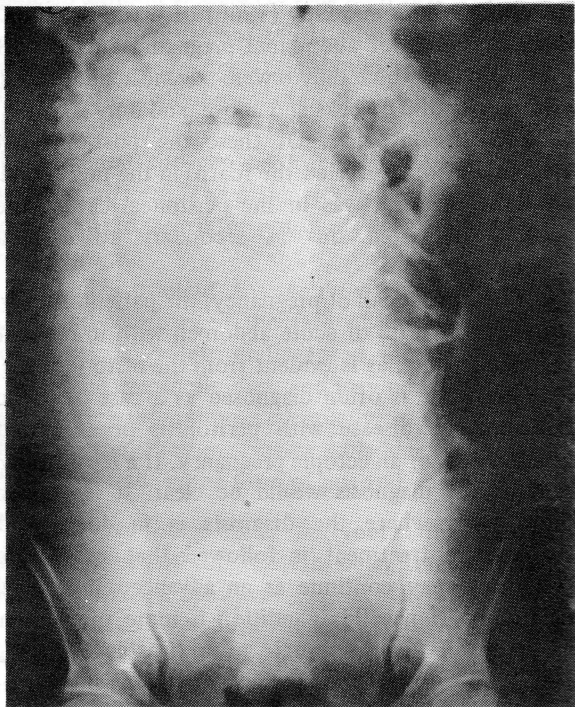
A diagnosis of extra uterine pregnancy was made. A laparotomy revealed first the placenta attached to the omentum and deriving its main blood supply from the ovarian blood vessels of the left side through the infundibulo-pelvic ligament. The foetus was behind the placenta. The amniotic sac was intact with scant liquor. A live female

Fig. I



Shows the foetus high up in the transverse lie with the foetal skull overlapping the ribs on the left side.

Fig. II



Shows no uterine shadow around the foetus and maternal intestinal gas shadows intermingling with the foetal parts.

infant (wt. 2.076 kg) was delivered. The placenta was separated from adhesions of the omentum and intestines and removed completely. There were multiple fibroids of the uterus. The left tube could not be visualised – presumptively being

ruptured giving way to the secondary abdominal pregnancy. The post operative period was uneventful.

Case No. 2

A.M. aged 30, para 2 + 3, Gr. 6. was admitted to the hospital on 8.6.79 from the Antenatal Clinic.

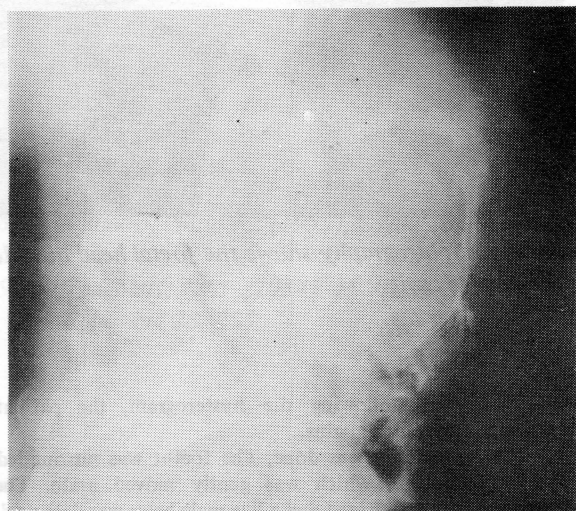
The patient was not sure of her dates but vaguely stated that she had missed her period in October 1978, so presumably her last period was in September 1978 and the expected date in June 1979. She had been attending a peripheral clinic from 7th March 1979.

The antenatal records showed that the attending nurses had recorded the height of fundus as 30 weeks. No definite decision had been made concerning the position and presentation of the foetus, or on the engagement of the head! The B.P. ranged between 120-140 mmHg systolic, by diastolic 80-90 mmHg. She had had 2 courses of chloroquine.

After 5 visits to the peripheral clinic she was referred to hospital with the remark "foetal parts – not felt, FHS, position, presentation not determined". The patient came to the labour room complaining of abdominal pains on 1.6.79. Again the findings were vaguely presented as height of fundus = 38 weeks and lie, presentation and position not determined. The Medical Officer suspected twins, asked for a straight X-ray and discharged her the next day as a case of false labour with X-ray showing single foetus and advised to attend the antenatal clinic.

When first seen in the antenatal clinic she appeared to be a complacent looking Zambian lady, in fair health, BP 130/90, Hb. 11.6 gm%, wt. 57 kg with no albumen or sugar in the urine.

Fig. III



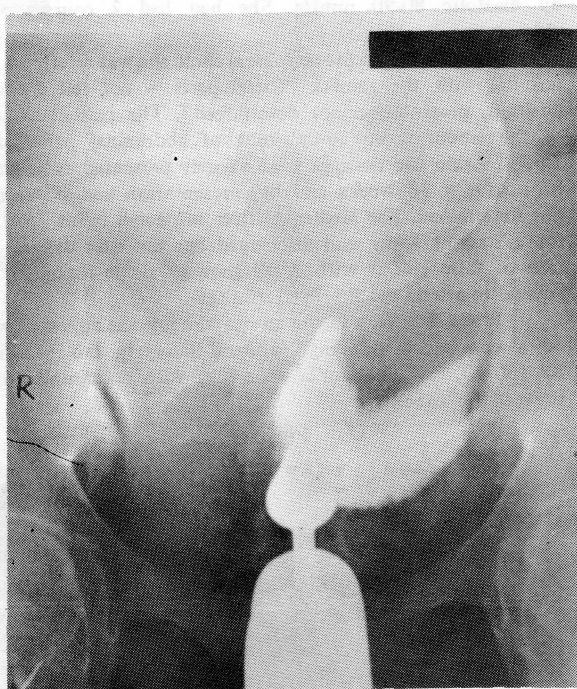
Foetal skull overshadowing the maternal vertebrae on lateral view.

On abdominal examination, the foetal parts were felt superficially, the head was high up, cephalic presentation and the fetal heart was clearly heard. The pregnancy appeared to be 34-36 weeks. The pelvic cavity was empty and since the

patient did not give any history of vaginal bleeding episodes, placenta previa was ruled out. Abdominal pregnancy seemed very probable.

Vaginal examination revealed the uterus to be anteverted, 8-10 weeks size with a soft cervix. A tentative diagnosis of advanced extra uterine pregnancy was made and the patient was admitted for further investigations and management. X-ray examination (Fig. II) revealed a foetus showing no uterine shadow around the foetus and the maternal intestinal gas shadows intermingled with the fetal parts. Figure III showed foetal parts over-shadowing the maternal vertebrae. Hysterography showed a normal sized uterine mass with the foetal head outside the uterine cavity (Fig. IV).

Fig. IV



Hysterosalpingography shows the foetal head outside the uterine cavity.

The day following the hysteroqram, the patient developed false labour pains.

A laparotomy was done. The foetus was surrounded by the omentum, which was gently moved aside. The amniotic sac was ruptured and a live male baby was delivered. The umbilical cord was clamped and cut. The placenta was found to be partly adherent to the intestines, mesentery and partly to the inferior margin of the liver. At first it was decided to leave the placenta in situ but then an attempt was made to take it out. It was easily separated from the liver but while separating it from the intestines, a small ileal perforation occurred. This was immediately repaired with chromic catgut. There was considerable haemorrhage on separating the placenta from its various attachments, but the

whole placenta was removed. The uterus was about 10 weeks size. Tubes could not be identified.

The patient made an uneventful recovery. The baby appeared to be at full term and weighed 2.8 kg.

Six weeks after in the postnatal clinic the patient complained of slight abdominal pain but there was no other significant finding.

COMMENTS

The term "abdominal pregnancy" means pregnancy within the peritoneal cavity. Almost always abdominal pregnancy follows early tubal abortion or rupture of a tubal pregnancy, with secondary implantation on the peritoneal surfaces. Primary abdominal pregnancy is extremely rare and virtually impossible to prove, except in an experimental animal. However, in a review of literature Teneblatt (1954) has reported 25 patients in whom no evidence of previous implantation could be established.

The incidence of advanced abdominal pregnancy is so rare that Gordon King (1953) reports that in his 25 years of work in China and Hong-Kong, he met with only 12 cases of advanced extra uterine pregnancy. Clark and Guy (1966) of Washington DC report 26 cases of abdominal pregnancies over a 18 year period of which only 8 were advanced abdominal pregnancies of 37 weeks and above, and only 2 babies were taken out alive. Of these the post-operative diagnosis of one revealed the foetus in the uterus and only the placenta was in the peritoneal cavity; the authors attributed this as secondary to criminal interference.

In the first half of pregnancy, the patient usually presents as a case of acute abdomen with infrequent vaginal bleeding, as is evident from the history of the first case. She is often diagnosed as a case of pelvic inflammatory disease with peritonitis or a twisted ovarian cyst or an ectopic pregnancy. If a laparotomy is done the diagnosis would be clear. It is only in those cases where the diagnosis is in doubt and conservative treatment is followed that an ectopic pregnancy may continue as an advanced abdominal pregnancy. Hence this condition is more often seen in the lower socio-economic group (Foster & Moore, 1967) who do not seek medical assistance in time — so that an ectopic pregnancy may continue as an advanced abdominal pregnancy.

The clinical feature of the second case is typical of the way an advanced abdominal pregnancy may present in the last trimester. The distinctive features are often a persistently abnormal lie of the foetus, superficially palpable foetal parts, the height of the uterine fundus may or may not correspond to dates

and a uterine contraction cannot be rubbed up. Finally it is very important to find a uterine mass separate from the foetus in the vaginal examination. All these clinical features were distinctly demonstrated in case No. 2. Certainly one of the reasons for the diagnosis being so often missed is a low index of suspicion due to the rarity of this condition. Eastman (1961) reports an incidence of 1 in 15,000 deliveries, while Beacham (1962) gives an incidence of 1 in 13,371.75 deliveries. Cross et al (1954) give an incidence of 1 in 2,207 deliveries, reporting 19 cases over an 18 year period. In 1979 there were 3 cases in 19,000 deliveries at the University Teaching Hospital, Lusaka, giving an incidence of 1 in 6,333 deliveries. Two cases were diagnosed and had live babies.

More recently workers have resorted to specialised examinations like aortography, uterine phlebography and isotopic placentography — in an attempt to reach a diagnosis. Very often such patients may be mistaken for placenta praevia, or ruptured uterus, while some patients have been repeatedly induced without success for post-maturity.

Once a diagnosis of advanced abdominal pregnancy is made, operation should be done without delay. Occasionally observation may be justified if the patient comes in the last trimester. The hazards of the placental site can be just as catastrophic at 28 weeks as at term. The major risk in allowing a patient to continue to term is the possibility of intraperitoneal haemorrhage.

In his brilliant Joseph Price Oration, Gordon King has summarised the fate of the extra-uterine foetus, if it is left undiagnosed in the abdomen. The foetus eventually dies, and may undergo maceration and suppuration, eventually being extruded through the rectum, vagina, bladder or anterior abdominal wall, in the form of pus and bones.

On the other hand the foetus may undergo mumification and calcification, being retained in the abdomen as a lithopaedian.

Management of the placenta at laparotomy is by far the greatest problem in treatment. Particular attention should be given to the location and accessibility of the blood supply.

At times it has also been advocated that the placenta should be left behind if it is adherent to a vital structure or major blood vessel. Convalescence is stormy and morbidity higher if the placenta is left behind. It can be removed at a later date. Hreshchychshyn et al (1967) used methotrexate and found a decrease in placental mass — as well as

clinical improvement in the patient. In both our cases, we were fortunate in being able to take out an intact placenta.

ACKNOWLEDGEMENT

We thank Mr Ansary of the Medical Illustration Department for the photographs, and Mrs Mary Chirwa and Miss Maria Kafwariman for their co-operation in typing out the article.

REFERENCES

1. Beacham, W.D. et al (1962) *American Journal of Obst. Gynae.* 84: 1257.
2. Clark, J.F.L., Guy, R.S. (1966), *American Journal of Obst. Gynae.* 96, 4, 571.
3. Cross, J.B. et al, (1951), *American Journal of Obst. Gynae.* 62: 303.
4. Eastman, N.J., and Hellman, L.M.: *Williams Obstetrics*, ed. 12, New York, 1961, Appleton-Century.
5. Foster, W.F., and Moore, D.T. (1967), *Obstetrics and Gynaecology* 30, 249.
6. King, G. (1954), *American Journal of Obst. Gynae Joseph Price Oration, USA*, 67, 712.
7. Hreshchychshyn, M.M. et al (1965), *American Journal of Obst. Gynae.* 93, 286.
8. Williams, Philip F.: (1955), *Gynec. Tr.* 78: 3.
9. Teneblatt, W.: (1954) *M. Ann. District of Columbia* 23: 255.